

American Clinical Neurophysiology Society Guideline 2: Guidelines for Standard Electrode Position Nomenclature

Jayant N. Acharya,* Abeer Hani,† Janna Cheek,‡ Partha Thirumala,§ and Tammy N. Tsuchida||¶#

*Department of Neurology, Penn State University Hershey Medical Center, Hershey, PA, U.S.A.; †Department of Pediatrics and Internal Medicine, Division of Neurology, Gilbert and Rose-Marie Chagoury School of Medicine Lebanese American University, Byblos, Lebanon; ‡NeuroLinks Group, LLC, Tulsa, OK, U.S.A.; §Department of Neurological Surgery and Neurology, University of Pittsburgh Medical Center, Pittsburgh, PA, U.S.A.; Departments of ||Neurology and ¶Pediatrics, George Washington University School of Medicine and Health Sciences, Washington, DC, U.S.A.; and #Division of Neurophysiology, Epilepsy and Critical Care in Center for Neuroscience and Behavioral Health, Children's National Health System, Washington, DC, U.S.A.

Summary: This revision to the EEG Guidelines is an update incorporating current electroencephalography technology and practice and was previously published as Guideline 5. While the 10-10 system of electrode position nomenclature has been accepted internationally for almost two decades, it has not been used universally. The reasons for this and clinical scenarios when the 10-10 system provides additional localizing information are discussed in this revision. In

addition, situations in which AF1/2, AF5/6, PO1/2 and PO5/6 electrode positions may be utilized for EEG recording are discussed.

Key Words: Electroencephalography electrode position, 10-10 System, International 10-20 system, Adult, Pediatric.

(J Clin Neurophysiol 2016;33: 308–311)

The 10-20 system of electrode placement, proposed by the International Federation of Societies for Electroencephalography and Clinical Neurophysiology in 1958,¹ has been the international standard for recording routine scalp EEG for clinical use. This system provides a consistent and replicable method of recording EEG with 21 electrodes placed at relative distances (10% or 20%) between the cranial landmarks over the head. It has also been used as a standard relative head surface-based positioning method for recording evoked and event-related potentials and for various transcranial brain mapping methods.

The development of multichannel EEG hardware systems and topographic source localization methods has resulted in the availability and frequent use of higher EEG electrode density with improved spatial resolution. Therefore, a modification, termed the 10-10 system, was proposed and accepted as a standard by the American Clinical Neurophysiology Society² and the International Federation of Clinical Neurophysiology.³ This provided nomenclature guidelines for several additional electrodes in the anteroposterior, coronal, and inferior planes.

With the availability of EEG systems capable of recording with a greater number of channels (e.g., 128, 256), there is a need to standardize the placement of additional electrodes. A further extension of the 10-10 system, called the 10-5 system, has been proposed,⁴ but not been accepted by the American Clinical Neurophysiology Society or the International Federation of Clinical Neurophysiology.

This guideline describes the method for combining a slight modification of the International 10-20 system with a slight modification of the combinatorial rule, described below in the

desirable characteristics, which allows for an extension of the 10-20 system to designate the 10% electrode positions. This extension is designated the 10-10 system. The guideline also discusses the clinical context for the use of the 10-20 and 10-10 systems.

This report is divided into the following sections: (1) desirable characteristics of an alphanumeric nomenclature; (2) head diagram of the “modified combinatorial nomenclature”; (3) explanation of the modification of the 10-20 nomenclature within the modified combinatorial 10-10 system; (4) explanation of the deviation from a strict combinatorial nomenclature in the modified system; (5) extension of combinatorial nomenclature to positions inferior to those demonstrated in Fig. 1; (6) clinical context for use of the two systems. Use of EEG electrode position nomenclature for purposes other than clinical EEG, as well as the proposed 10-5 system will not be discussed further in this study.

I. DESIRABLE CHARACTERISTICS OF AN ALPHANUMERIC NOMENCLATURE

1. The alphabetical part should consist of one but no more than two letters.
2. The letters should be derived from names of underlying lobes of the brain or other anatomic landmarks.
3. The complete alphanumeric term should serve as a system of coordinates, locating the designated electrode according to the following rules.
 - a. Each letter should appear on only one coronal line. (In standard 10-20 terminology, the only outstanding exception to this rule are the “T” (temporal) names that appear on both the central and parietal coronal lines. For reasons discussed in the *Explanation of the modification of the 10-20 nomenclature within the modified combinatorial system* section, this exception is replaced by a more consistent terminology within the

Address correspondence and reprint requests to Jayant N. Acharya, MD, DM, Department of Neurology, Penn State University Hershey Medical Center, 30 Hope Drive, EC037 Hershey, PA 17033, U.S.A.; e-mail: jacharya@hmc.psu.edu.
Copyright © 2016 by the American Clinical Neurophysiology Society
ISSN: 0736-0258/16/3304-0308
DOI 10.1097/WNP.0000000000000316

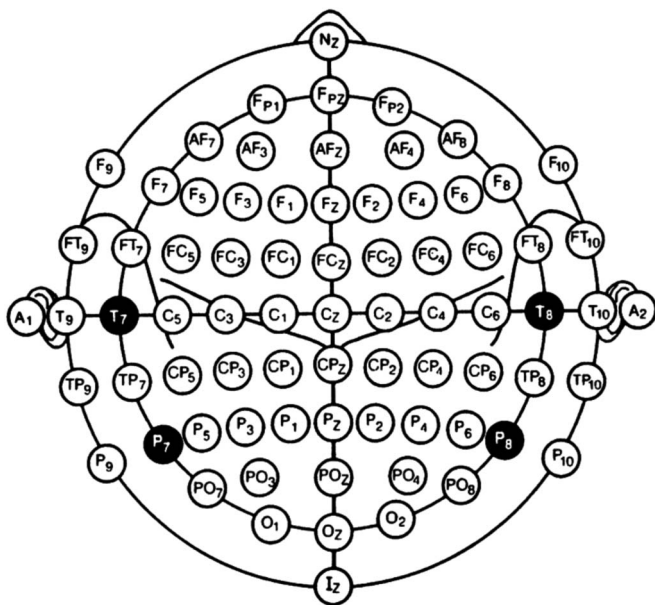


FIG. 1. Modified combinatorial nomenclature for the 10-10 system.

nomenclature. For emphasis, this modification is displayed on the head diagram in the Head diagram of the 10-10 system section with white lettering on a black background.)

- b. Each number should designate a sagittal line so the same postscripted number identifies all positions lying on that sagittal line. (Again, the only outstanding exception to this rule in the current 10-20 system is in the “T” numbering. For example, this results in the F7, T3, and T5 designations all appearing on a single sagittal line. This exception is also eliminated within the recommended nomenclature. Once more for emphasis, this modification is displayed in the head diagram in Fig. 1 with white lettering on a black background.)

II. HEAD DIAGRAM OF THE 10-10 SYSTEM

In Fig. 1, the modifications of the current 10-20 terminology, instituted for reasons explained in the next section, are emphasized by displaying them with white lettering on a black background.

III. EXPLANATION OF THE MODIFICATION OF THE 10-20 NOMENCLATURE WITHIN THE MODIFIED COMBINATORIAL SYSTEM

The modified 10-10 terminology replaces the inconsistent T3/T4 and T5/T6 terms with the consistent T7/T8 and P7/P8. The head diagram in Fig. 1 emphasizes consistency of the terms T7/T8 and P7/P8 by showing them with white lettering on black circles. The value of this becomes evident when inspecting the head diagram, which shows that, except for Fp1/Fp2 and O1/O2, all electrode positions along the same sagittal line have the same postscripted number and that all electrodes designated by the

same letter(s) lie on the same coronal line. Thus, the alphanumeric nomenclature for each electrode specifies its coordinate location within the 10-20 grid system. Once this is done, the positions 10% inferior to the standard frontotemporal electrodes are easily designated as F9/F10, T9/T10, and P9/P10.

As indicated above, the straightforward designation of an electrode's coordinate localization by its nomenclature requires replacement of the inconsistent T3/4 by T7/8, which is a readily understandable modification. A more radical modification replaces T5/6 by P7/8. However, even with this more radical departure, P can be recognized as representing parietal when it is associated with a postscripted number with a value of 6 or less, whereas it can be recognized as implying posterior temporal if P is associated with a number with a value of 7 or greater.

However, even though T7/8 and P7/8 in the head diagram emphasize the internally consistent logic of the system, it would clearly be an acceptable alternative to continue to use T3/4 and T5/6 without detracting from the logic of the remaining system.

IV. EXPLANATION OF THE DEVIATION FROM A STRICT COMBINATORIAL NOMENCLATURE IN THE MODIFIED SYSTEM PROPOSED HEREIN

The 10-20 system does not name electrode positions forming the four 10% intermediate coronal lines lying between the five standard coronal lines containing currently named electrode positions. The strict combinatorial system designates the currently unnamed positions by combining the names or letters for the two standard electrode positions that surround a currently undesigned 10% intermediate electrode position.

Thus, positions in the second intermediate coronal line are designated as either the frontotemporal positions (FT) or the frontocentral positions (FC), depending on their location as noted in the head diagram.

The electrode positions in the third intermediate coronal line are designated as temporal-posterior temporal (TP) or centroparietal (CP) as noted in Fig. 1.

The positions in the fourth and final intermediate coronal line are designated as posterior temporo-occipital (PO) or parieto-occipital (PO).

The only proposed deviation from the strict combinatorial rule discussed above is in naming the first intermediate transverse positions as anterior frontal (AF) electrodes rather than frontopolar-frontal electrodes. The latter terminology would designate the electrodes with either three letters (FpF) or the same two letters (FF). Since neither of these letter designations is desirable (the first because it uses three letters and the second because it uses the same letter twice), the Committee proposed using the readily understandable anterior frontal (AF) designation displayed in Fig. 1.

Once the above letters are assigned to the currently unnamed 10% intermediate positions, then their alphanumeric designation is completed by postscripting the letters assigned to an electrode by the number designating the sagittal line on which the electrode

lies. For example, in Fig. 1, AF3, FC3, CP3, and PO3 all lie on the same sagittal line designated by the number 3.

As noted in Fig. 1, only one electrode position is placed between AFz and AF7 (AF3) and between AFz and AF8 (AF4). Similarly, there is only one electrode between POz and PO7 (PO3) and between POz and PO8 (PO4). Because of the short anatomic distance between the two points, placing additional electrodes (such as AF1/2, AF5/6, PO1/2, PO5/6), would result in excessive crowding and may be clinically impractical. However, they could be used in patients with large head sizes if clinically feasible and necessary.

When this is done, each new alphanumeric designation is not only directly related to a slight modification of the 10-20 terminology but also serves as an internally consistent coordinate system that locates each newly designated electrode position at the intersection of a specified coronal (identified by the prefixed letter) and sagittal (identified by the postfixed number) line.

V. EXTENSION OF THE 10-10 COMBINATORIAL NOMENCLATURE TO POSITIONS INFERIOR TO THOSE DEMONSTRATED IN FIGURE 1

Positions posterior to electrodes displayed in the ninth and tenth rows would be designated as PO9 (10% inferior to PO7), PO10 (10% inferior to PO8), O9 (10% inferior to O1), and O10 (10% inferior to O2). Electrodes 10% inferior to the ninth row would be designated with the postscripted number 11 (F11, FT11, T11, TPI1, P11, PO11, and O11), and those 10% inferior to the tenth row would be designated with a postscripted number 12 (F12, FT12, T12, TPI2, P12, and O12).

VI. CLINICAL CONTEXT

The additional, more closely spaced electrodes in the 10-10 system clearly provide better spatial resolution, but there are some practical concerns with its routine use for all EEGs. Placement of several additional electrodes requires increased time and effort on the part of technologists, potentially reducing the number of studies that can be performed in a day. Additional electrodes need to be purchased. Routine EEGs are ordered or recorded for a variety of indications, and it is not clear whether the extra electrodes provide clinically meaningful additional information in situations where localization of an epileptiform abnormality is not critical (for instance, in patients with encephalopathy or other generalized abnormalities). Also, most vendors of commercial EEG machines in the United States continue to provide headboxes with electrode positions and nomenclature limited to the 10-20 system. A commitment from the vendors to switch to the 10-10 system would be necessary to promote universal use of the 10-10 system for all EEG studies.

The change in nomenclature from T3/T4 and T5/T6 to T7/T8 and P7/P8 is essentially a conceptual one. However, one does not intuitively think of P7/P8 electrodes as overlying the temporal region rather than the parietal region. Although this is consistent with the logic proposed in the 10-10 system, it appears to be contrary to one of the desirable characteristics of an alphanumeric

nomenclature (the letter should indicate the underlying lobe of the brain). *It should be emphasized to trainees that P represents parietal when it is associated with a postscripted number with a value of 6 or less and implies posterior temporal if P is associated with a number with a value of 7 or greater.* Also, EEG machine vendors would need to change the labeling of electrodes in headboxes.

Nevertheless, the additional electrodes included in the 10-10 system can be very useful in certain clinical situations. During long-term video-EEG studies of patients undergoing presurgical evaluation, they can provide more precise localizing information with regard to interictal epileptiform discharges and ictal EEG onsets. In patients with suspected temporal lobe epilepsy, the limitations of the 10-20 system for precise localization have been recognized for several decades, leading to the use of additional noninvasive (T1/T2 electrode positions proposed by Silverman) and semi-invasive electrodes (nasopharyngeal, sphenoidal). Use of the temporal electrode positions described in the 10-10 system (FT7/FT8, FT9/FT10, T9/T10) can be particularly helpful in such patients and may obviate the need for T1/T2 electrodes. Despite being measured in different ways, the positions of FT9/FT10 electrodes closely approximate those of T1/T2 electrodes. Although some controversy persists, several studies have suggested that anterior temporal electrodes detect interictal and ictal epileptiform abnormalities virtually as well as do sphenoidal electrodes. They also provide more consistent recording information, do not result in pain and discomfort for patients and do not require physician expertise.⁵ Nasopharyngeal leads provide less information, are uncomfortable for patients, and are prone to artifacts and therefore should be avoided for routine clinical use.⁶ Similarly, in patients with mesial frontal lobe epilepsy, some of the electrodes from the 10-10 system (FC1/FC2, FCz, C1/C2, CP1/CP2, and CPz) in addition to the 10-20 system may be helpful to best delineate the epileptic focus. Other electrode positions could be used selectively in other types of focal epilepsies as well, but the entire set of electrodes described in the 10-10 system may not always be necessary even for presurgical video-EEG monitoring.

Using all of the >70 electrode positions described in the 10-10 system, and even additional electrode positions, is likely to be of greatest value when advanced digital studies, such as source localization and electrical source imaging, are performed in addition to standard visual analysis of the EEG.

RECOMMENDATIONS

Although the decision regarding use of appropriate electrode positions should be individualized depending on the clinical need in a given patient, taking all of the factors discussed above into consideration, a reasonable clinical approach would be as follows:

1. For routine EEGs, where the indication is not epilepsy or localization of an epileptic focus is not critical, the 10-20 system may be clinically adequate for most patients and efficient in terms of time, effort, and cost. It may also be sufficient for many diagnostic (such as distinguishing between epileptic and psychogenic events) long-term ambulatory and inpatient video-EEG monitoring studies.

2. Because of its greater spatial resolution, the 10-10 system provides better localizing information and should be used in patients undergoing presurgical evaluation in the epilepsy monitoring unit. However, not all of the electrode positions need be used; selective electrode positions can be chosen based on the suspected location of the epileptic focus. Additional electrodes from the 10-10 system may also be used sometimes during routine EEGs, when an attempt is made to localize the epileptic focus in patients with suspected focal epilepsy, and during certain diagnostic ambulatory and video-EEG studies (for instance, in patients with psychogenic events versus frontal lobe seizures).
3. The entire set of 10-10 electrode positions, with or without additional electrodes, can be used if additional digital analysis, including source localization and electrical source imaging, is planned.
4. Although it would be desirable to switch to T7/T8 and P7/P8 for both clinical and educational (including publication) purposes, it would be an acceptable alternative to continue to use T3/4 and T5/6, or to use both terms, at present. Modification of commercially available EEG machine headboxes to reflect the change and education of trainees will likely lead to gradual acceptance of the new terminology.

DISCLAIMER

This statement is provided as an educational service of the American Clinical Neurophysiology Society (ACNS). It is based

on an assessment of current scientific and clinical information. It is not intended to include all possible proper methods of care for a particular problem or all legitimate criteria for choosing to use a specific procedure. Neither is it intended to exclude any reasonable alternative methodologies. ACNS recognizes that specific patient care decisions are the prerogative of the patient and the physician caring for the patient, based on all of the circumstances involved. The clinical context section is made available to place the evidence-based guidelines into perspective with current practice habits and challenges. Formal practice recommendations are not intended to replace clinical judgment.

REFERENCES

1. Jasper HH. The 10-20 electrode system of the International Federation. *Electroencephalogr Clin Neurophysiol* 1958;10:367–380.
2. American Electroencephalographic Society. Guideline thirteen: guidelines for standard electrode position nomenclature. *J Clin Neurophysiol* 1994;11:111–113.
3. Nuwer MR, Comi G, Emerson R, et al. IFCN standards for digital recording of clinical EEG. *Electroencephalogr Clin Neurophysiol* 1998;106:259–261.
4. Oostenveld R, Praamstra P. The five percent electrode system for high-resolution EEG and ERP measurements. *Clin Neurophysiol* 2001;112:713–719.
5. Blume WT. Controversy: the necessity for sphenoidal electrodes in the presurgical evaluation of temporal lobe epilepsy: con position. *J Clin Neurophysiol* 2003;20:305–310.
6. Sperling MR, Engel J. Electroencephalographic recording from the temporal lobes: a comparison of ear, anterior temporal and nasopharyngeal electrodes. *Ann Neurol* 1985;17:510–513.